Chronic Open Abdomen With Fistula

Dietmar Wittmann, MD, PhD, FACS

Patient's Age: 63
Case Year: 1995
Number of STAR Entries: 10
Diagnoses Keywords: Fistula, Diverticulitis, Hernia

History

Abdomen with Colostomy,
Hernia and Fistula

Two years prior to transfer to our institution the patient underwent a Hartmann's operation for diffuse peritonitis from perforated diverticular abscess of the sigmoid colon. Post operatively he required relaparotomy for persisting peritonitis with abdominal hypertension and the abdomen was left open. Once infection was controlled, multiple attempts to close the abdomen with various meshes failed and a bowel fistula developed (he had received radiation therapy for prostatic adenocarcinoma in the past).

The patient was told that eventually skin would cover the wound. He refused to have a split thickness skin graft and was desperate about his huge abdominal wall hernia, also because he could not control colostomy and fistula output. He was ready to take any risk to repair his huge hernia and agreed to be paralyzed with full respirator support for at least one week while undergoing Staged Abdominal Repair (STAR).

Granulation Tissue Covering Center of Hernia with Fistula Orifice

The patient's general health was relatively good and I planned to solve his surgical problem by closing the fistula &colostomy and redevelop the fascia that was retracted sideways to permit fascial suture closure without mesh because there was no fascial loss as the fascia had only retracted sideways during the two years without median anchoring.

Diagnoses:

1. Chronic open abdomen
2. Failed hernia mesh repair
3. Small bowel fistula
4. Colostomy after Hartmann’s procedure
5. Diverticulitis
6. Diffuse peritonitis

Hospital Course

Opening a Space Through Dense Adhesions

Day 1 - STAR #1

Removal of most of the Marlex mesh, difficult lysis of all adhesions and en-block resection of a small bowel segment with the fistula and running single layer end-to-end anastomosis using 4x0 Maxon. Abdominal washout and takedown of the colostomy and end-to end anastomosis between colon and remaining well perfused sigmoid using the same suture technique. Inspection of the remaining abdomen,

washout and meandering positioning of small bowel.

Suturing the bur closure device (Wittmann Patch®) to re-identified fascial edges using O-loop running nylon sutures to distribute tension evenly to the fascial borders. Loose closing of the bur sheets to accommodate the expected peritoneal edema from operative manipulations. Kerlex Gauze, suction drain, Hypopack and immediate application of suction to the hermetically seal wound space by hooking the drain to a suction pump in the operating room.

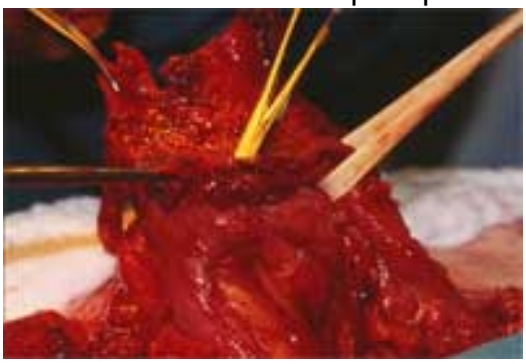

Colostomy Resected from Opening Through Abdominal Wall

Day 2 - STAR #2

The abdomen is swollen as expected. In spite of the loose bur closure, IAP is 24 mmHg. Opening of the bur and washout. Inspection of the two anastomoses. Both are well perfused, and healing. Inspection of the remaining bowel, no leak. Four serosal defects from previous manipulations are healing well. There is no purulent fluid in the sub- and supra hepatic and splenic spaces, in the paracolic gutters and pelvis. Gentle stretching of fascia using the bur sheets. Hypopack closure. Suction attached and transport to ICU.

Day 3 - STAR #3

Removal of hypopack, Opening of artificial bur The abdomen is still edematous. IAP was16 mmHg. Inspection of the two anastomoses. Both are well perfused. Inspection and digital exploration of the remaining bowel without disturbing its meandering position by seperating fibrin adhesions. There is no leak. Wash out, also of the sub- and supra hepatic and splenic spaces, in the paracolic gutters and pelvis. Gentle stretching of fascia using the bur sheets. Hypopack closure. Suction applied and transport to ICU.

Small Bowel Removed with
Stent in Resected Fistula

Day 4 - STAR #4

Removal of hypopack, opening of artificial bur. Peritoneal fluid is clear. Inspection of the two anastomoses. A small spot at the proximal anastomosis is dark and my lead to a leak. It is over sown imbricating the dark spot. Washout and further inspection reveals no pathology. Gentle stretching of fascia using the bur sheets. Hypopack closure. Suction applied and transport to ICU.

Day 5 - STAR #5

Removal of hypopack, opening of artificial bur. Peritoneal fluid is clear. Inspection of the two anastomoses. The over sown small spot at the proximal anastomosis is healing. Washout and further inspection reveals no pathology. Gentle approximation of fasciae using the bur sheets. The free edge of the hook sheet can be trimmed off by 3cm. The distance between the fascial edges is now about 10 cm. Hypopack closure. Suction applied and transport to ICU.

Resected Fistula

Day 6 - STAR #6

Removal of hypopack, opening of artificial bur. Peritoneal fluid is clear. Anastomoses and sutured area is healing well. Wash out and inspection. More forceful approximation of fascia using the bur sheets.. The distance between the fascial edges is now about 8 cm. Hypopack closure. Suction applied and transport to ICU.

Day 8 - STAR #7

Removal of hypopack, opening of artificial bur. Peritoneal fluid is clear. Anastomoses and sutured area is healing well. Wash out and inspection. Further more forceful approximation of fascia using the bur sheets. The free edge of the hook sheet can be trimmed off by 2 cm. The distance between the fascial edges is now about 6 cm. Hypopack closure. Suction applied and transport to ICU.

Day 10 - STAR #8

In the ICU - Removal of hypopack, opening of artificial bur. Peritoneal fluid is clear. Anastomoses and sutured area is healing well. Wash out and inspection. Further more forceful approximation of fascia using the bur sheets. The distance between the fascial edges is now about 4 cm. Hypopack closure. Suction applied and

transport to ICU.

Day 12 - STAR #9

In the ICU - Wash out and inspection. The fascia has not suffered from all manipulations and is well perfused and vital. Further more forceful approximation of fascia using the bur sheets. The distance between the fascial edges is now close and we plan to close the abdomen the next day. The patient is still intubated and paralyzed. Hypopack closure. Suction applied and transport to ICU

Day 14 - STAR #10

Removal of hypopack, opening of artificial bur. Pulling the bur sheets brings the fascial edges together for fascial suture. Abdominal x-ray. The bur is removed and the fascia closed using interrupted No. 1 Maxon sutures (Klöppel Technique) The patient is still intubated and paralyzed. Hypopack closure. Suction applied and transport to ICU.

Outcome

The patient was extubated on post op day one, had bowel movements on post op day 5 and was discharged to rehab on postop day 7. His abdomen remained closed and there were no complications, no hernia, no fistula no wound infection and he was happy to proceed with a normal life.

- Alive - yes
- Hernia – no

A Note from Dr. Wittmann

The particular issue with this case is that the fascia needed to be brought to the midline after it had retracted away from the midline over the past 2 years. As there was no fascial loss, stretching the fascia was an option to re-establish and intact abdominal envelope for this patient. Using a mesh was not a good option because previous attempts to close with Marlex had failed and there was bacterial contamination of the entire open wound, albeit well guarded by granulation tissue.

Fascial stretching, however, required neutralizing physiologic muscular counteraction by a conscious patient for abdominal wall pain. Therefore, we needed to paralyze the patient, eliminate pain and artificially ventilate for a longer period and account for all potential complications associated with such aggressive therapy – a decision that is not easy in the face of an otherwise healthy individual.

The patient wanted to be cured and when I asked him if he would accept the risk of not surviving even if it were a higher than 50%, he still wanted treatment to terminate his desolate abdominal condition.

This was also the first time that I used STAR to treat a chronic hernia with fistula. On the other hand I felt comfortable doing STAR because up to that point I had done more than 400 STAR abdominal entries and had researched antimicrobial therapy to be able to prevent fulmination infection and sepsis in this patient.

Re-stretching the abdominal wall fascia was easier than I thought. After 3 weeks the patient was ambulating with an intact abdominal wall envelope and the few Marlex mesh piece that remained were incorporated in the scar.

The other interesting point is that STAR permits continuous inspection and action before the complication – an anastomotic leak in this case may have jeopardized the entire procedure if I had not overseen the critical area early. STAR also gives you the safety to take down a colostomy and monitor the anastomosis to the intact rectal stump.

For more information, visit www.openabdomen.org [1]

Source URL (retrieved on *12/22/2013 - 8:50am*):
http://www.surgicalproductsmag.com/articles/2011/01/chronic-open-abdomen-fistula?qt-most_popular=0

Links:
[1] http://www.openabdomen.org