The Port Site Closure Problem

Anne-Marie Gannon, Clinical & Regulatory Affairs Specialist, neoSurgical

This article appeared in the November/December issue of Surgical Products.

Laparoscopy has been incorporated into routine surgical practice due to its minimally invasive nature and associated advantages. (1,2) Its introduction also brought new clinical complications, however, including trocar site herniation (TSH). TSH remains a serious problem today, often requiring emergency reoperation for repair. In the absence of surgical intervention, TSH can lead to morbidity due to small bowel strangulation and incarceration. Despite this potential morbidity, the problem of TSH is frequently overlooked in clinical practice. This may be due to a lack of awareness, inappropriate follow-up, and patient unwillingness to report the problem to a physician. (1)

There is a general consensus in the literature that preventative measures should be taken to avoid the occurrence of herniation at the port site. (1,2) Fascial closure has been recommended as a means of TSH prevention. One study reported a statistically higher frequency of hernias at 12 millimeter port sites where the fascia was left open (8 percent) compared with those that were closed (0.22 percent) following gynecologic laparoscopy. (3)There is a general consensus that the underlying fascia of all port sites greater than or equal to 10mm should be closed due to an increased risk of herniation. (1,3,4) Although routine closure of smaller ports may not be necessary, it is recommended that the underlying fascia be

closed if they have been subjected to extensive manipulation. (5,6)

Apart from trocar size, a number of other technical risk factors are associated with TSH. One such factor is port location, with several reports suggesting that umbilical sites are at a greater risk of herniation compared with lateral port sites. (1,7,8) This has been attributed to weakness of the fascia and absence of supporting muscle in this area. (1,2) Enlargement or stretching of a port site during specimen extraction has also been associated with a greater risk of hernia development. (9,10) Patient-related risk factors that have been associated with TSH include high BMI. (8,11–13) This has been attributed to increased intra-abdominal pressure and increased abdominal wall thickness. (2,14) Additionally, wound infection has been suggested as a predisposing factor to hernia development. (15) Fascial closure is recommended for umbilical ports, port sites that have been stretched or enlarged for specimen retrieval, and trocar sites in obese patients.

A number of methods for port site closure have been developed in an attempt to prevent TSH, but there is still no gold standard. Traditional suturing techniques have been used, but these have proven to be difficult due to blind closure of the fascial defect. (16) Modified hand suturing techniques (17–19) have also been applied with varying degrees of success. Many of these methods are technically-challenging, with surgeons having to grapple with the problem of locating sutures within the abdomen. Several suturing techniques require user skill and do not always result in consistent outcomes for the patient. Effective port site closure is particularly challenging in obese patients. This is due, at least in part, to the difficulties of finding the rectus sheath and suturing through the layers of a thicker abdominal wall through a relatively small hole. (13,16.)

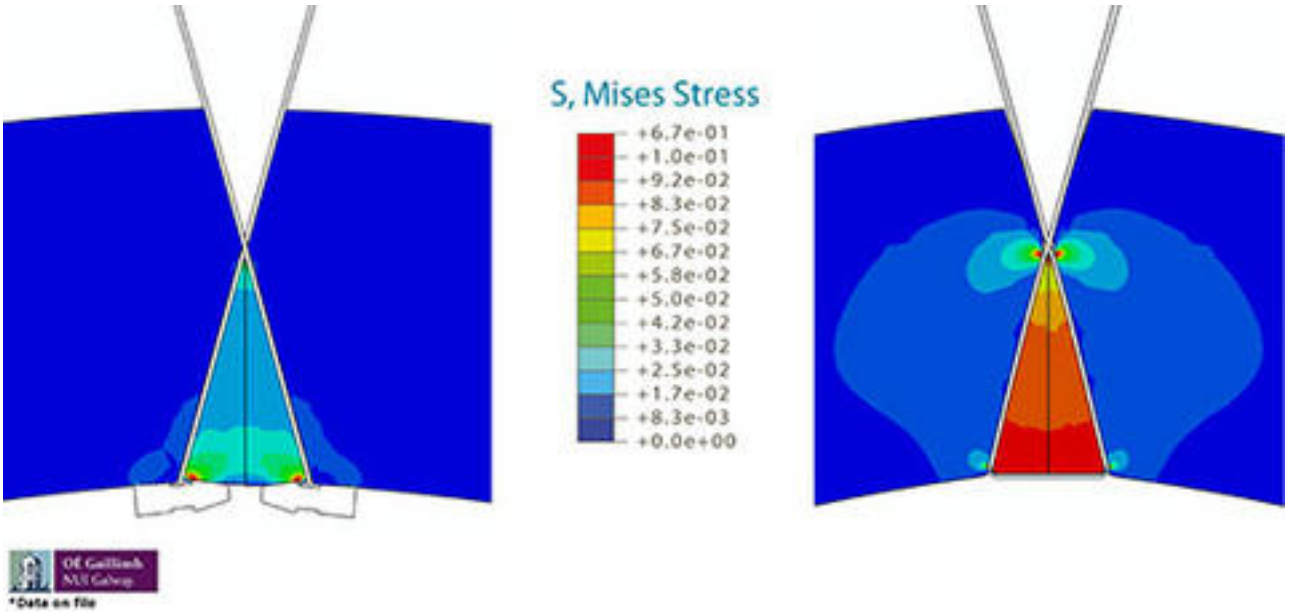

Figure 1

More recently, a first generation of device-based solutions has come to the market. Some have been associated with promising results with respect to TSH prevention. (9,20,21) However, a major issue associated with closure devices is post-operative

pain. One study reported a 5 percent incidence of clinically significant pain associated with fascial closure of port sites in the lower abdomen following laparoscopic gynecologic surgery. (22) This pain was attributed to nerve entrapment by the implanted sutures used for approximation of the defect. Surgical intervention to release the fascial stitch was effective in alleviating pain. The authors of that study concluded that careful re-approximation of fascial edges, avoiding an excessively tight closure, may decrease the risk of nerve compression. It has been reported that over-tightened sutures can lead to tissue necrosis and excessive tissue overlap, which results in reduced tensile strength in the healed tissue. (23)

Achieving the balance of effective approximation without excessive tension can be difficult when using devices that provide “closed loop” approximation. A recently developed next generation fascial approximation device called neoClose facilitates a different type of approximation. This approximation method, referred to as Vector X Closure (Figure 2), is facilitated by the delivery of two absorbable AutoAnchors into the abdominal wall. These are used by the surgeon to approximate the tissue on either side of the incision site. This type of approximation is intended to reduce tension at wound sites compared to more traditional closed loop methods (Figure 1). On this basis, the risk of nerve compression associated with neoClose is expected to be lower than for devices that provide closed loop approximation. Minimizing wound tension during approximation is also expected to contribute to a suitable environment for optimal wound healing. (24)

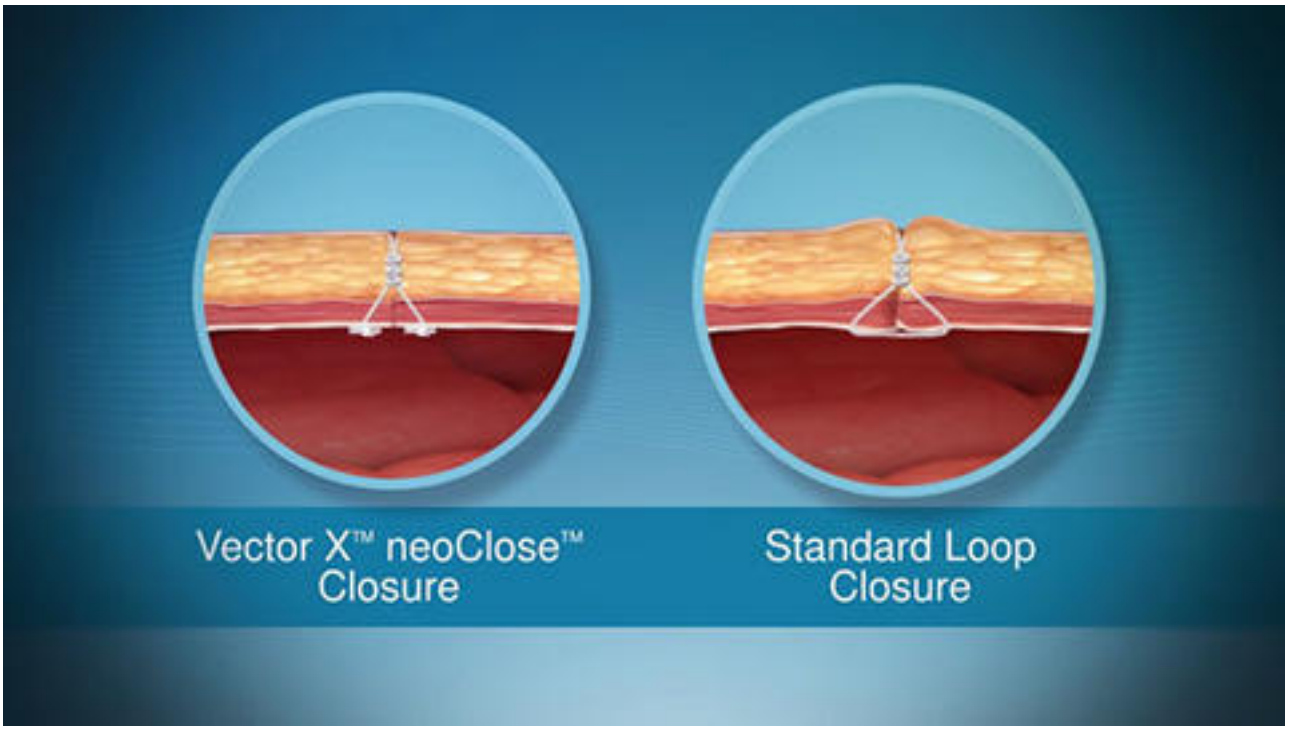

Figure 2

With increasing emphasis on procedural safety and cost-effectiveness in today’s OR, surgical teams are faced with the challenging task of reducing post-operative complications. Solutions that enable safer surgery, faster recovery time and better outcomes are required. For laparoscopic surgery, this will include technologies that

lead to reduced post-operative pain and a lower risk of herniation. The advent of technologies that offer a consistent positive outcome will be a welcome benefit for both patient and surgeon.

1. Owens, M., Barry, M., Janjua, A. Z. & Winter, D. C. A systematic review of laparoscopic port site hernias in gastrointestinal surgery. Surg. J. R. Coll. Surg. Edinb. Irel. 9, 218–224 (2011).
2. Swank, H. A. et al. Systematic review of trocar-site hernia. Br. J. Surg. 99, 315–323 (2012).
3. Kadar, N., Reich, H., Liu, C. Y., Manko, G. F. & Gimpelson, R. Incisional hernias after major laparoscopic gynecologic procedures. Am. J. Obstet. Gynecol. 168, 1493–1495 (1993).
4. Lajer, H., Widecrantz, S. & Heisterberg, L. Hernias in trocar ports following abdominal laparoscopy. A review. Acta Obstet. Gynecol. Scand. 76, 389–393 (1997).
5. Romagnolo, C. & Minelli, L. Small-bowel occlusion after operative laparoscopy: our experience and review of the literature. Endoscopy 33, 88–90 (2001).
6. Yamamoto, M., Minikel, L. & Zaritsky, E. Laparoscopic 5-mm trocar site herniation and literature review. JSLS J. Soc. Laparoendosc. Surg. Soc. Laparoendosc. Surg. 15, 122–126 (2011).
7. Azurin, D. J., Go, L. S., Arroyo, L. R. & Kirkland, M. L. Trocar site herniation following laparoscopic cholecystectomy and the significance of an incidental preexisting umbilical hernia. Am. Surg. 61, 718–720 (1995).
8. Uslu, H. Y. et al. Trocar site hernia after laparoscopic cholecystectomy. J. Laparoendosc. Adv. Surg. Tech. A 17, 600–603 (2007).
9. Shalhav, A. L. et al. Transperitoneal laparoscopic renal surgery using blunt 12-mm trocar without fascial closure. J. Endourol. Endourol. Soc. 16, 43–46 (2002).
10. Skipworth, J. R. A., Khan, Y., Motson, R. W., Arulampalam, T. H. & Engledow, A. H. Incisional hernia rates following laparoscopic colorectal resection. Int. J. Surg. Lond. Engl. 8, 470–473 (2010).
11. Parker, H. H., 3rd, Nottingham, J. M., Bynoe, R. P. & Yost, M. J. Laparoscopic repair of large incisional hernias. Am. Surg. 68, 530–533; discussion 533–534 (2002).
12. Bowrey, D. J. et al. Risk factors and the prevalence of trocar site herniation after laparoscopic fundoplication. Surg. Endosc. 15, 663–666 (2001).
13. Sanz-López, R. et al. Incisional hernias after laparoscopic vs open cholecystectomy. Surg. Endosc. 13, 922–924 (1999).
14. Hussain, A. et al. Long-term study of port-site incisional hernia after laparoscopic procedures. JSLS J. Soc. Laparoendosc. Surg. Soc. Laparoendosc. Surg. 13, 346–349 (2009).
15. Crist, D. W. & Gadacz, T. R. Complications of laparoscopic surgery. Surg. Clin. North Am. 73, 265 (1993).
16. Shaher, Z. Port closure techniques. Surg. Endosc. 21, 1264–1274 (2007).
17. Lasheen, A. E., Elzeftawy, A., Ahmed, A.-H. M. & Lotfy, W. E. Anatomical closure of trocar site by using tip hole needle and redirecting suture hook. Surg. Endosc. 24, 2637–2639 (2010).
18. Su, W.-H. et al. Port wound closure assisted by Foley catheter: an easier way to provide fascia security. J. Obstet. Gynaecol. Res. 35, 725–731 (2009).

19. Stringer, N. H. et al. New closure technique for lateral operative laparoscopic trocar sites. A report of 80 closures. Surg. Endosc. 9, 838–840 (1995).
20. Eid, G. M. & Collins, J. Application of a trocar wound closure system designed for laparoscopic procedures in morbidly obese patients. Obes. Surg. 15, 871–873 (2005).
21. Lee, M. & Donovan, J. F. Laparoscopic omentectomy for salvage of peritoneal dialysis catheters. J. Endourol. Endourol. Soc. 16, 241–244 (2002).
22. Shin, J. H. & Howard, F. M. Abdominal wall nerve injury during laparoscopic gynecologic surgery: incidence, risk factors, and treatment outcomes. J. Minim. Invasive Gynecol. 19, 448–453 (2012).
23. Greenberg, J. A. & Clark, R. M. Advances in suture material for obstetric and gynecologic surgery. Rev. Obstet. Gynecol. 2, 146–158 (2009).
24. Nawaz, Z. & Bentley, G. Surgical incisions and principles of wound healing. Basic Ski. 29, 59–62 (2011) .

Source URL (retrieved on *04/25/2014 - 5:58am*):
http://www.surgicalproductsmag.com/articles/2013/11/port-site-closure-problem